



# A Surgical Approach to Location-specific Neuropathic Foot Ulceration

Michael D. Liette, DPM<sup>a</sup>, Peter A. Crisologo, DPM<sup>a</sup>,  
Lance J. Johnson, DPM<sup>a</sup>, Jordan A. Henning, DPM<sup>b</sup>,  
Edgardo R. Rodriguez-Collazo, DPM<sup>c</sup>, Suhail Masadeh, DPM<sup>d,\*</sup>

## KEYWORDS

- Ulceration • Neuropathy • Diabetes • Tendon • Flexible • Semirigid
- Lower limb reconstruction • Limb salvage

## KEY POINTS

- Persistent hyperglycemia leads to muscle imbalance, increased tendon stiffness, and the creation of biomechanical deformity.
- Biomechanical deformity in neuropathic patients leads to localized increased plantar pressures and eventual ulceration development.
- Deformities must be flexible or semirigid to allow for offloading through tendon balancing.
- Patients with ulceration who undergo amputation are likely to undergo further amputations because of increasing deformities and biomechanical imbalance.
- Addressing deformities early, before the development of infection or worsening ulceration, may lead to better outcomes and fewer complications.

## INTRODUCTION

Neuropathic foot ulcerations, often caused by diabetes, are complex, costly, and require extensive resources.<sup>1–3</sup> There are currently no accepted algorithms to address the cause of the deforming forces contributing to wound creation. This failure contributes to the high rates of recurrence often seen following primary resolution through

---

<sup>a</sup> University of Cincinnati Medical Center, 231 Albert Sabin Way, ML 0513, Cincinnati, OH 45276, USA; <sup>b</sup> University of Cincinnati Medical Center, Staff Podiatrist Cincinnati Veterans Affairs Medical Center, 580 Walnut Street, Apt 803, Cincinnati, OH 45202, USA; <sup>c</sup> Department of Surgery, Presence Saint Joseph Hospital, Adults & Pediatric Ilizarov Limb Deformity Correction, Peripheral Nerve Reconstructive Microsurgery, 2913 North Commonwealth Avenue, Chicago, IL 60657, USA; <sup>d</sup> University of Cincinnati Medical Center, Director of Podiatric Surgery Residency University of Cincinnati Medical Center, Cincinnati Veteran Affairs Medical Center, 231 Albert Sabin Way, ML 0513, Cincinnati, OH 45276, USA

\* Corresponding author.

E-mail address: [masadesb@uc.edu](mailto:masadesb@uc.edu)



local wound care.<sup>4–8</sup> This failure can be mitigated through the use of tendon transfers and balancing procedures in the flexible or semirigid osseous deformity. These transfers serve not as functional procedures but as a means of alleviating a deforming force created from underlying disorder. It is well known that the nonenzymatic glycosylation process leads to alterations in tendon structure and function, ultimately creating contracture and deformity. This process is not limited to a single tendon but occurs in all of the tendons throughout the foot and ankle. There is strong evidence to support these procedures, with selection based according to specific ulcer location and the flexibility of the deformity. Although neuropathy, peripheral vascular disease, and other medical comorbidities should be identified and addressed accordingly, the focus in this article is on the surgical approach to correct the deformities contributing to ulceration. The article proposes a treatment algorithm to address flexible or semirigid deformities and evaluate the current literature regarding their site-specific outcomes.

### ***Proposed Surgical Algorithm***

#### ***Distal digital ulcerations (plantarflexed digit)***

**Introduction** Digital deformities lead to the formation of preulcerative and ulcerative lesions, which are a common and challenging problem treated by the podiatric profession. These lesions may quickly progress to deeper ulcerations and eventual amputation given the underlying complex causes creating the deformity. They are often associated with poor outcomes with conservative treatments because of the difficulty in adequately offloading this area. Percutaneous flexor tenotomy offers a minimally invasive technique to alleviate the deforming forces and restore normal anatomic alignment of the digit.

**Technique** The ulcerative digit is hyperextended with the ankle in dorsiflexion to bowstring the flexor tendons. A stab incision is made percutaneously either plantar to the middle phalanx, to isolate the flexor digitorum longus (FDL) tendon, or just proximal to the web space to isolate both the FDL and the flexor digitorum brevis (FDB) tendons. The incision is typically made with an #11 blade, 18-gauge needle, or a beaver blade to transect the tendons, taking care to avoid the surrounding neurovascular bundles. The toe is then splinted in extension to prevent adhesions and promote scar formation in the corrected position. This technique is shown in [Fig. 2](#).

**Results** Several current studies have evaluated the efficacy of percutaneous tenotomies as treatment of preulcerative or ulcerative lesions of the distal digit. The results of the studies of FDL and FDB percutaneous tenotomies for digital ulcerations are summarized in [Table 2](#).<sup>9–15</sup>

**Discussion** Deformities of the toes, specifically claw toes and hammertoes, frequently develop in diabetic patients because of long-standing sensorimotor neuropathy leading to intrinsic biomechanical abnormalities.<sup>16</sup> Because of the failure of the lumbricals and interossei muscles, the long flexors and extensors gain advantage, which forces the toes into a hammered or clawed position and leads to a displacement of the weight-bearing plantar pulp of the toe, forcing the tip of the apical tuberosity, with a thin soft tissue envelope, to bear the entire weight of the body.<sup>17</sup> This area is the most common site for diabetic ulceration, attributed to the high rates of the intrinsic-minus foot type seen within the diabetic population (3%).<sup>18,19</sup> These lesions are often treated conservatively through various offloading measures such as padding, taping, or custom orthoses and extradePTH shoes. Even with the most aggressive conservative regimen, they remain difficult to adequately offload long



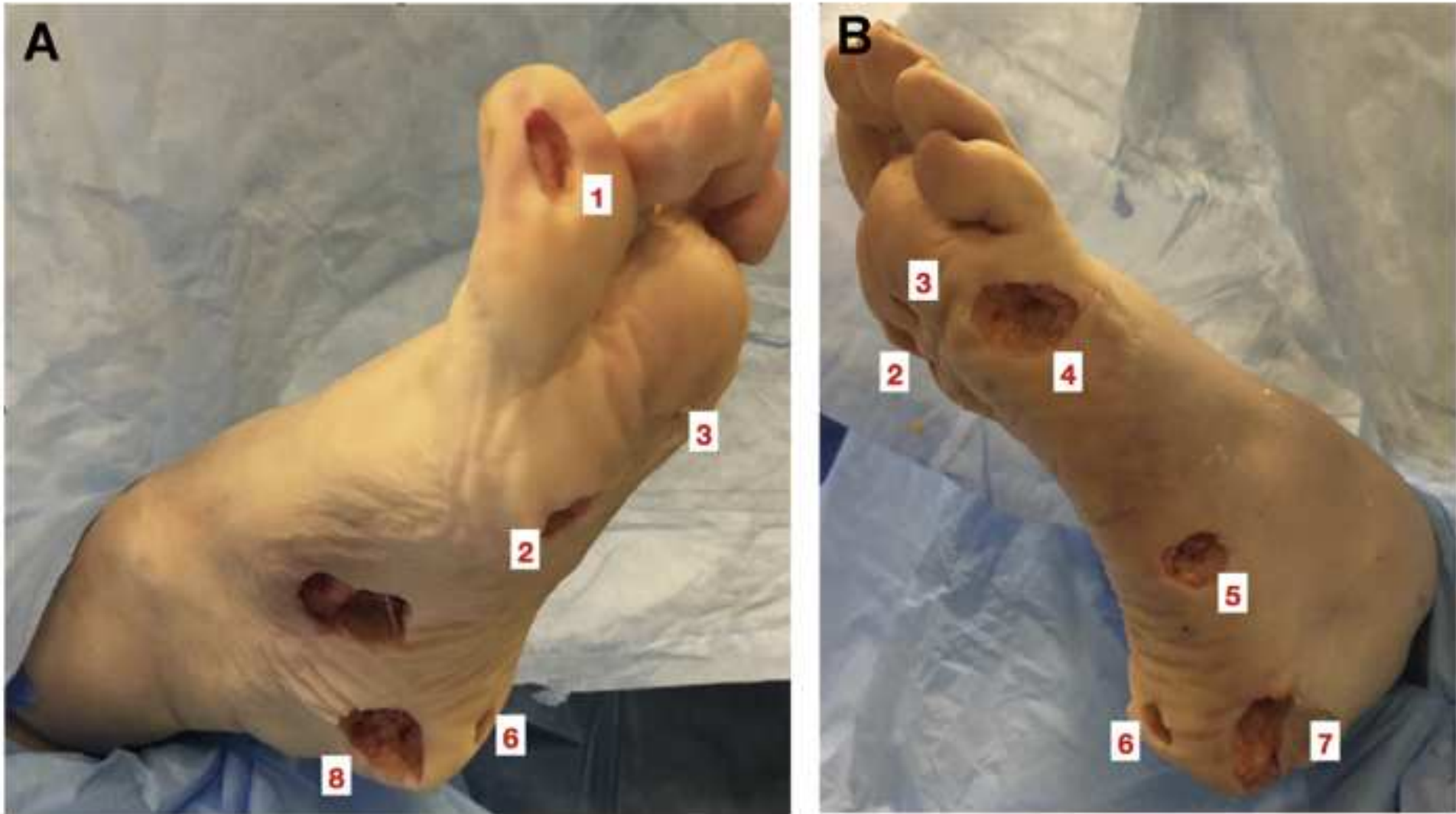
**Table 1**  
Summary of proposed treatment algorithm based on location-specific neuropathic ulceration

Anatomic Ulcer Location	Biomechanical Position	Deforming Force	Treatment	Figs. 1 and 2 Location
Distal digits	Plantarflexed digit	Flexion contracture	Flexor tenotomy PIPJ/DIPJ	1
Sub-first metatarsophalangeal joint	Forefoot valgus	Plantarflexed first ray: overpowering peroneus longus or weak tibialis anterior	Peroneus longus lengthening vs peroneus longus to peroneus brevis tenodesis	2
Sub-2/3/4 metatarsophalangeal joints	Equinus/planus	Contracted triceps surae	Gastrocnemius-soleus lengthening/ triceps surae lengthening	3
Sub-metatarsophalangeal joints	Cavus	Weak posterior compartment musculature/contracted plantar fascia	Plantar fasciotomy (selective vs complete)	3
Sub-fifth metatarsophalangeal joint	Forefoot varus	Overpowering tibialis anterior tendon	Tibialis anterior tendon transfer, STATT, tibialis anterior tendon lengthening	4
Styloid process fifth metatarsal base	Forefoot varus	Overpowering tibialis anterior tendon	Tibialis anterior tendon transfer, STATT, tibialis anterior tendon lengthening	5
Plantar central calcaneus	Calcaneal gait	Weak/overlengthened triceps surae	Flexor hallucis longus tendon transfer	6
Plantar lateral calcaneus	Hindfoot varus	Overpowering posterior tibial tendon	Tenotomy posterior tibial tendon	7
Plantar medial calcaneus	Hindfoot valgus	Overpowering peroneus brevis	Peroneus brevis tendon lengthening/ posterior tibial tendon tightening	8

See [Fig. 1](#) for clinical correlation.

*Abbreviations:* DIPJ, distal interphalangeal joint; PIPJ, proximal interphalangeal joint; STATT, split tibialis anterior tendon transfer.

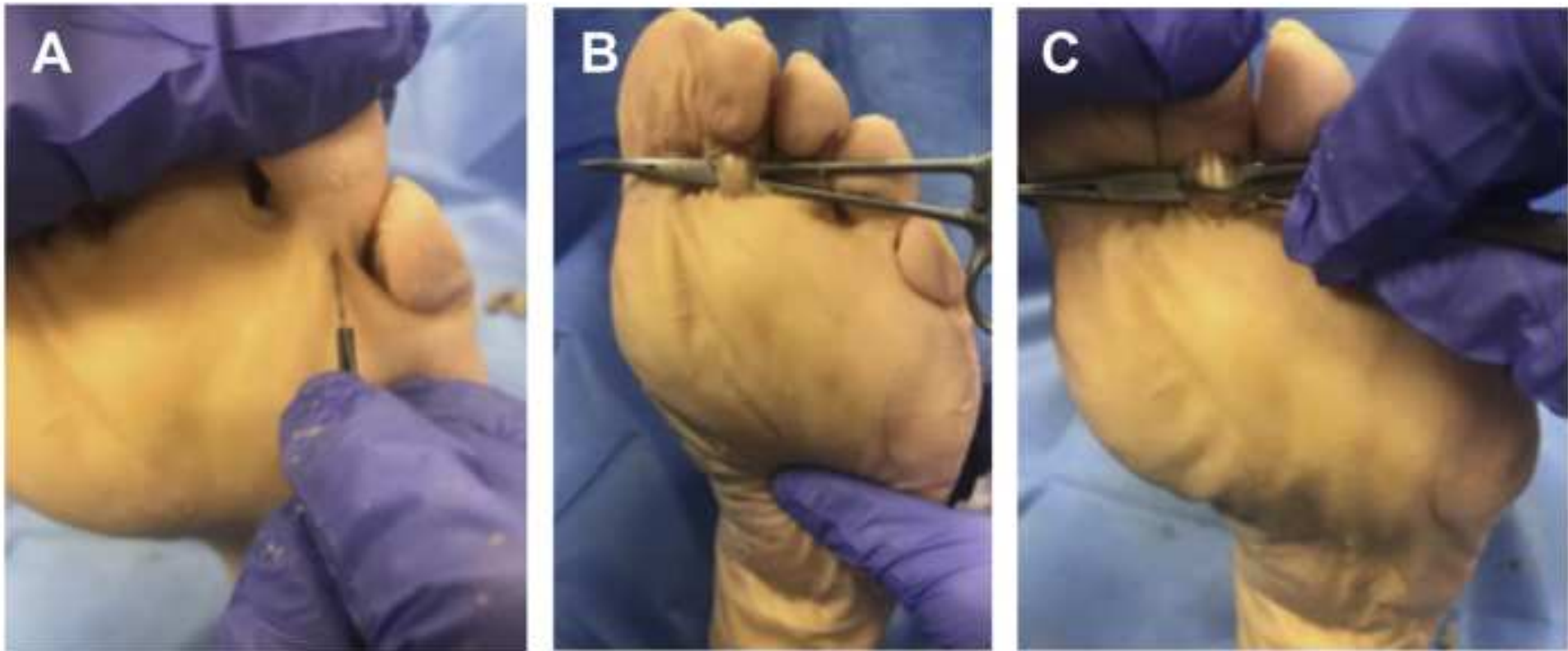




**Fig. 1.** Common decubitus ulcer locations recreated in a cadaver laboratory with corresponding numerical values as outlined in the last column of [Table 1](#). Numbers 1 to 8 are as described in [Table 1](#). (Courtesy of S. Masadeh, DPM, Cincinnati, OH.)

term, and tend to recur after healing is achieved. Performing a lasting procedure to reduce the deforming forces and restore the proper weight-bearing surface of the toe is key for long-term success.

There seems to be a consensus in the literature regarding the efficacy of percutaneous flexor tenotomy for digital ulcerations. Healing rates are reported between 92% and 100%, regardless of the method or tendons transected. Complications of the procedure included recurrence, shifted/transfer lesions, hyperextension deformities, and the potential for neurovascular compromise. All of these were seen with low rates of occurrence after performing this minimally invasive procedure.<sup>9–15</sup> Tamir and colleagues,<sup>13,14</sup> Kearney and colleagues,<sup>9</sup> and Van Netten and colleagues<sup>15</sup>



**Fig. 2.** (A) Stab incision made overlying the flexor digitorum tendons. (B) Flexor tendons isolated and exposed to protect neurovascular bundle. (C) Flexor tendon transected while maintaining protection of the adjacent neurovascular bundles. (Courtesy of S. Masadeh, DPM, Cincinnati, OH.)



**Table 2**  
Summary of the literature for percutaneous tenotomy for flexible digital deformities

	Tenotomies (N)	Follow- up (mo)	Healed (N)	Recurrence (N)	Tendons	Complications	Time to Healing
Laborde et al, <sup>10</sup> 2007	28	28	100% (28)	10% (3)	FDL/FDB	0	2 mo
Tamir et al, <sup>13</sup> 2008	34	13	100% (34)	0% (0)	—	0	3 wk
Schepers et al, <sup>12</sup> 2010	42	11	100% (42)	2.3% (1)	FDL/FDB	0	3 wk
Kearney et al, <sup>9</sup> 2010	58	28	98.3% (57)	12.1% (7)	FDL	5	40 d
Rasumussen et al, <sup>11</sup> 2013	65	31	93% (60)	18% (5)	FDL/FDB	0	3 wk
Van Netten et al, <sup>15</sup> 2013	47	23	92% (43)	20% (7)	FDL	10	22 d
Tamir et al, <sup>14</sup> 2014	103	22	98% (101)	8% (9)	FDL	14	4 wk
Total	377	11–31	96.8%	8.49% (32)	Combined	7.96% (30)	3.94 wk

Data from Refs.<sup>9–15</sup>



performed tenotomies on isolated FDL tendons and showed the highest rate of recurrence and complications, compared with studies that transected both the FDL and the FDB tendons. Those studies that did not exclude toes with radiographic evidence of osteomyelitis experienced slower rates of healing, but this finding did not preclude performing a tenotomy on the ulcerative digit. Several of these toes went on to eventual amputation, but the results were mixed, with some healing achieved. Given the high rate of healing and low rates of complications/recurrence, percutaneous flexor tenotomies seem to have a valuable place in the wound care repertoire, providing good to excellent outcomes in those patients with distal toe ulcerations or preulcerative lesions.

### ***First metatarsophalangeal joint ulcerations (forefoot valgus)***

**Introduction** Ulcerations beneath the first metatarsal head are another common location. This area may prove devastating given the biomechanical importance of the first ray and the imbalance created after amputation. These ulcers are often treated conservatively, without an attempt at identifying the underlying cause and addressing the deforming force. The peroneus longus plantarflexes the first metatarsal and everts the foot during the stance phase of the gait cycle. As an increasing load is applied to the peroneus longus, significant eversion and plantarflexion of the first ray occurs,<sup>20</sup> which leads to an eversion, locking effect of the first ray, stabilizing the medial column and forcing the foot into a supinatory position.<sup>20</sup> A locked medial column, driven into further plantarflexion by continued action of the peroneus longus, effectively causes supination of the entire foot and the accompanying increase in plantar pressures beneath the first metatarsal head.<sup>21,22</sup>

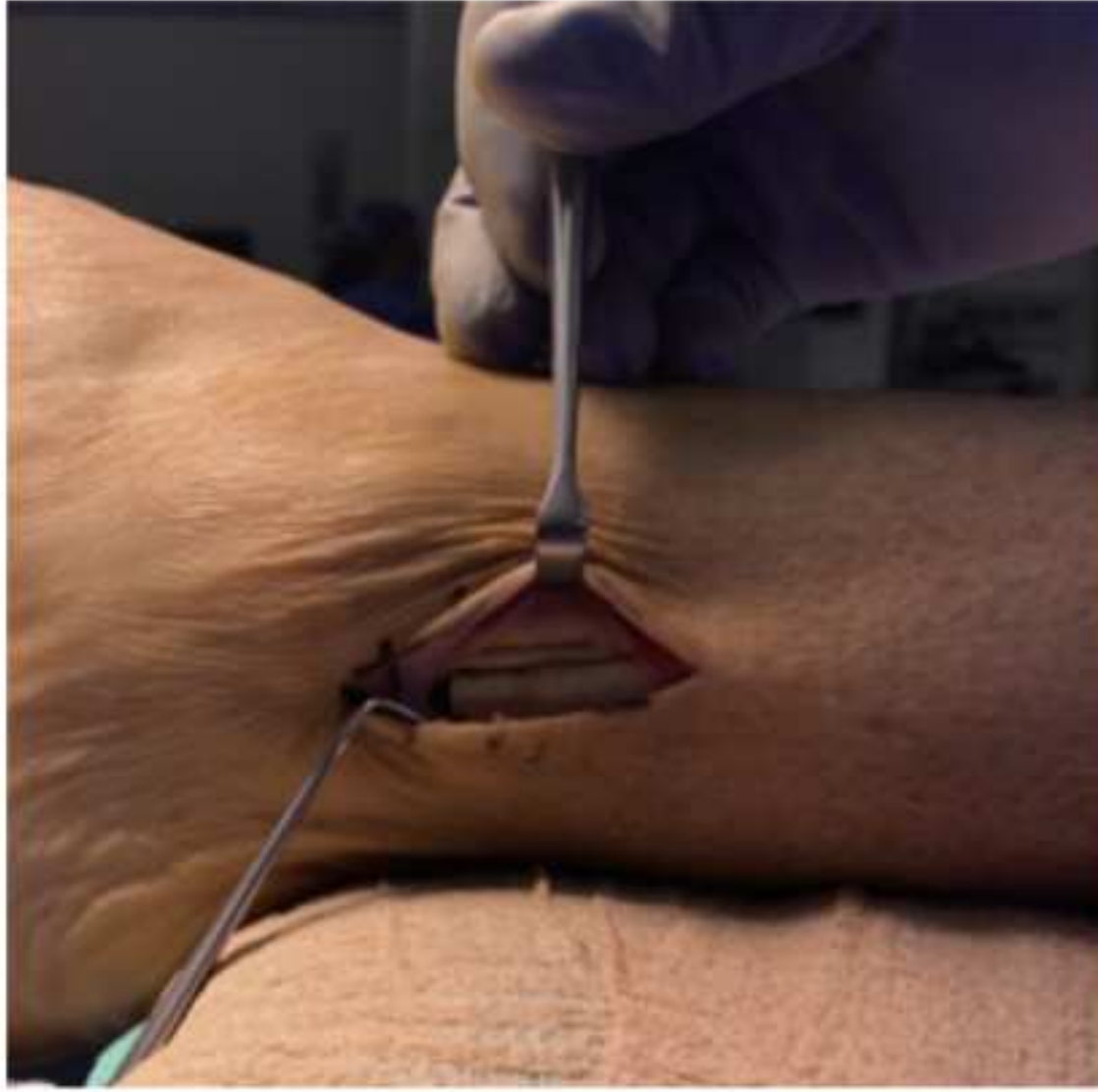Limited joint motion or plantarflexion has been proposed as the factor leading to increased plantar pressures and therefore ulceration or preulcerative lesions in the insensate foot.<sup>23–26</sup> Patients with a history of plantar first metatarsal head ulceration have been shown to have significantly less first ray mobility and higher plantar pressures as well as an inverse relationship between first ray dorsiflexion and peak pressure at the first metatarsal head.<sup>23</sup> Tenodesis of the peroneus longus has the power to remove the deforming force, in a flexible or semirigid deformity of the first metatarsal, and to prevent or heal ulceration.

**Technique** An incision is made posterior and superior to the lateral malleolus, approximately 4 cm in length, isolating and exposing the peroneal tendons. The peroneus longus tendon is then identified by plantarflexing the first metatarsal. A wedge of the tendon is removed, to prevent scarring or adhesion of the 2 transected ends. The proximal portion is then sutured to the peroneus brevis tendon under physiologic tension using polyethylene terephthalate suture. A splint is then applied and the patient is made non-weight-bearing for 4 to 6 weeks, as shown in [Fig. 3](#).

**Results** There are limited studies in the literature regarding the outcomes of isolated peroneus longus to brevis tendon transfer for treatment of a plantar first metatarsal head ulceration or preulcerative lesion. Studies performed by Roukis and colleagues<sup>27</sup> and DiDomenico and colleagues<sup>28</sup> show the potential of this procedure to offload the first metatarsal head, but most current literature focuses on its use as an adjunctive procedure when other procedures fail to eliminate the deformity. The results of these studies are summarized in [Table 3](#).<sup>29,30</sup>

**Discussion** The plantar aspect of the first metatarsal head is one of the most common locations for ulcer development in patients with diabetes.<sup>31,32</sup> This area can be disastrous, given the consequences of osteomyelitis of the first metatarsal and the





**Fig. 3.** The lateral malleolus is outlined and incision is planned for identification of the peroneal tendons. The peroneus longus tendon is isolated and transected. The proximal portion is then sutured to the peroneus brevis, completing the tenodesis. (Courtesy of S. Masadeh, DPM, Cincinnati, OH.)

biomechanical abnormalities of pursuant amputation. These drastic alterations in gait and pressure distribution after amputation contribute to early reulceration rates and additional tissue loss, which provides strong incentive to remove the deforming force early in an attempt at limb preservation.

Before performing the peroneus longus to brevis tendon transfer, a flexible or dynamic plantarflexed first metatarsal must be established clinically. It is important to establish the presence of peroneal overdrive or hyperactivity to ensure the effectiveness of this procedure in offloading the first metatarsal head. To do this, 1 thumb is placed underneath the lesser metatarsals and the other beneath the first metatarsal head or the ulcerative site. The patient then plantarflexes the ankle while the physician evaluates for further plantarflexion of the first metatarsal in relation to that of the lesser metatarsals, showing a flexible or semirigid deformity.<sup>28</sup> This deformity is often seen in the presence of a weak triceps surae, assisting in the overall plantarflexion of the foot through continued plantarflexion of the first ray, as well as with a weakened tibialis anterior muscle, the main antagonist to the peroneus longus.

The evidence supporting the peroneus longus to peroneus brevis tenodesis is currently limited, without any known studies that evaluate this procedure in isolation to cure or prevent ulceration of the plantar first metatarsal head. The current focus is the use of this procedure as an adjunct to others to further offload the first metatarsal head. Although neither of the 2 prior studies isolated the peroneus longus to brevis tenodesis to offload the first metatarsal head, they do show it as an effective means of reducing the deforming force and the pressures in this area. Hamilton and colleagues<sup>30</sup> and Dayer and Assal<sup>29</sup> used the procedure to further offload a continued plantarflexed first metatarsal after other procedures had failed to alleviate the deformity. Further studies evaluating the efficacy of isolated peroneal tenodesis in the treatment of plantar first metatarsal head ulcerations are needed.



Table 3 Results summary for peroneus longus to peroneus brevis tenodesis for flexible or semirigid plantarflexed first ray						
	Patients (N)	Procedures	Follow- up (mo)	% Healed (N)	% Recurrence (N)	Time to Healing (wk)
Hamilton et al, <sup>30</sup> 2005	10	Gastrocnemius recession, peroneus longus to brevis transfer, 2–5 metatarsal head resection	14.2	100% (10)	0% (0)	Not stated
Dayer et al, <sup>29</sup> 2009	21	Modified Jones tenosuspension, peroneus longus to brevis transfer, gastrocnemius recession	39.6	100% (21)	0% (0)	4.4

Data from Dayer R, Assal M. Chronic diabetic ulcers under the first metatarsal head treated by staged tendon balancing: a prospective cohort study. *J Bone Joint Surg Br.* 2009;91(4):487-93 and Hamilton GA, Ford LA, Perez H, et al,. Salvage of the neuropathic foot by using bone resection and tendon balancing: a retrospective review of 10 patients. *J Foot and Ankle Surg.* 2005;44(1): 37-43.

**Sub-second, third, fourth metatarsophalangeal joint ulcerations (equinus)**

**Introduction** Forefoot ulceration, located plantar to the metatarsal heads, is another common location for ulceration. Prolonged levels of persistent hyperglycemia produce high levels of nonenzymatic glycosylation of collagen fibers within the tendons, cross-linking the fibers via the Maillard reaction.<sup>33–35</sup> Electron microscopy studies of the Achilles tendon have shown irregularity of collagen fibrils with high levels of disorganization.<sup>33–36</sup> Continued hyperglycemic states produce a stiffening/shortening of the tendon, joint hypomobility, and, in turn, increased plantar pressures.<sup>33–36</sup> Studies have shown an increase in skin-collagen cross-linking concentrations, with an associated 54% increase in Achilles tendon stiffness, and a 33% higher forefoot/rearfoot peak plantar pressure ratio in patients with diabetes.<sup>36</sup> This deformity, or change in function, leads to an increased risk for the development of plantar ulceration<sup>37–40</sup> and has led to an ulceration rate up to 4 times the normal value compared with patients without associated ankle equinus.<sup>41</sup>

Equinus contracture of the ankle joint produces an increase in forefoot pressures and is present in as many as 37% of patients with diabetes, compared with 15% in patients without diabetes.<sup>41,42</sup> Evaluating for posterior contracture determines the necessity of an Achilles tendon lengthening versus a gastrocnemius recession in the treatment and prevention of ulcerative lesions. An equinus contracture can be isolated solely within the gastrocnemius muscle or can be located within the entirety of the gastrocnemius-soleus complex. It is critical to evaluate for the source of the contracture to ensure that appropriate procedure selection is pursued. A Silfverskiöld examination, performed by measuring ankle dorsiflexion with the knee in a flexed position and then again with the knee in an extended position, determines operative course.<sup>43,44</sup> An increase in range of motion of the ankle joint with the knee flexed compared with extended is considered a positive Silfverskiöld examination and the contracture is isolated to the gastrocnemius.<sup>43,44</sup> This examination has shown a



sensitivity of 89% and a specificity of 90% compared with goniometric evaluation and is vital in determining appropriate procedure selection.<sup>45</sup>

**Technique** The Achilles tendon is isolated and the foot is maximally dorsiflexed. Using a #15 or #11 blade, 3 vertical stab incisions are made midline over the Achilles tendon. The blade is inserted vertically and rotated medially or laterally, in an alternating fashion, releasing approximately 51% of the tendon fibers at each location. Incisions are made in 3-cm intervals from the insertion of the Achilles tendon, alternating from medial to lateral to medial to avoid sural nerve damage, as shown in [Fig. 4](#).

Gastrocnemius recession can be performed through multiple established surgical techniques. After a positive Silfverskiöld examination is identified, a Vulpius, Strayer, Baumann, or endoscopic gastrocnemius release may be performed to alleviate the isolated gastrocnemius contracture. Because this choice is often surgeon dependent and patient specific, the authors defer surgical technique to the individual performing the operation because multiple options are available.

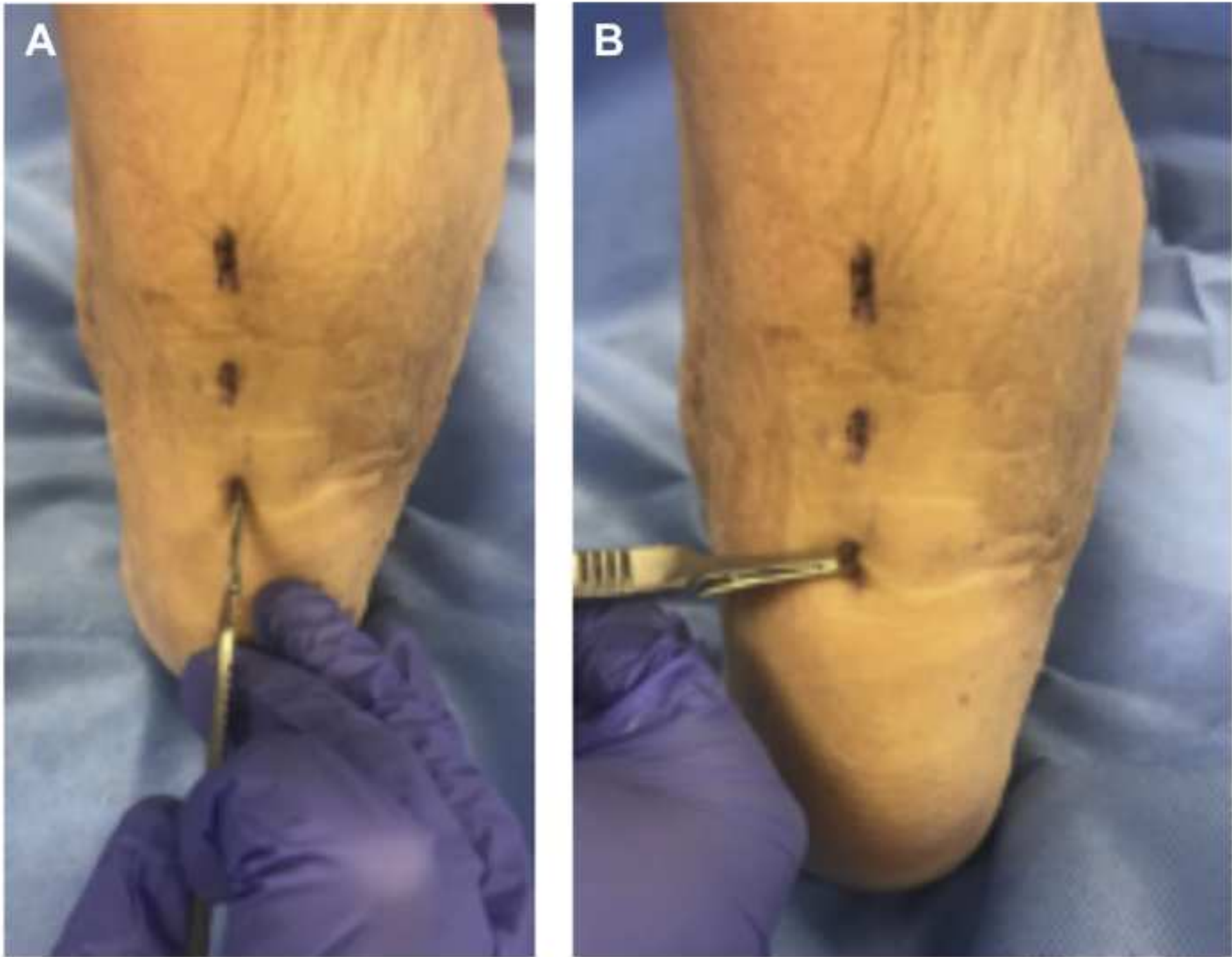
**Achilles tendon lengthening results** Several current studies have evaluated Achilles tendon lengthening as a treatment and for the prevention of neuropathic forefoot ulceration caused by ankle equinus of the gastrocnemius-soleus complex (a negative Silfverskiöld examination), and these are summarized in [Table 4](#).<sup>46–49</sup>

**Gastrocnemius recession results** The current literature regarding isolated gastrocnemius recession as treatment of plantar ulceration caused by ankle equinus localized within the gastrocnemius tendon (a positive Silfverskiöld examination) is limited, because this procedure is often used in conjunction with other procedures. Several studies were selected for further review of this procedure's effectiveness in treating forefoot ulceration, and they are summarized in [Table 5](#).<sup>29,30,33,50–53</sup>

**Discussion** The evidence for the effectiveness of an Achilles tendon lengthening has been well established in the literature. Of the studies evaluated in this review, a total of 265 lengthenings were performed and showed an approximate 97% healing rate with few complications. The major complications experienced in these studies were that of a ruptured Achilles tendon or a heel ulceration caused by the creation of a calcaneal gait after overlengthening of the tendon. The rate of recurrence varied from as low as 2% in the study performed by Colen and colleagues<sup>46</sup> to as high as 37% in the study performed by Mueller and colleagues.<sup>49</sup> These findings show that repeat procedures may be necessary because of continued persistent hyperglycemia and further contracture of the previously lengthened tendon. Armstrong and colleagues<sup>54</sup> evaluated mean peak pressures within the forefoot after percutaneous Achilles tendon lengthening and found an average reduction from 86 N preoperatively to 63 N postoperatively, further showing the power of this procedure to reduce high-pressure areas and to heal or prevent ulceration.

The current literature for isolated gastrocnemius recession to treat forefoot ulceration is limited, because most of the evidence evaluating this procedure is as an adjunct to others. The studies performed by Dayer and Assal<sup>29</sup> and Laborde and colleagues<sup>52,53</sup> were the largest and had the longest follow-up. They found high rates of healing, ranging from 90.9% to 95.8%, and rates of recurrence from 4.1% to 14%, respectively.<sup>29,52,53</sup> There were no complications experienced in any of the studies evaluated, likely because of the more controlled release of a gastrocnemius recession than that of an Achilles tendon lengthening. This procedure seems to have similar efficacy to the Achilles tendon lengthening in offloading forefoot ulceration, but, again, selection is driven by the results of the Silfverskiöld examination.





**Fig. 4.** (A) Achilles tendon identified and incisions placed at 3-cm intervals proximal to the insertion. (B) A 50% transection performed alternating from medial to lateral to medial to avoid damage to the sural nerve and allow adequate lengthening of the tendon. (Courtesy of S. Masadeh, DPM, Cincinnati, OH.)

Achilles tendon lengthening and gastrocnemius recession, when used appropriately, have shown excellent results in healing forefoot ulcerations with low rates of complications and recurrence. Because of the high rates of ankle equinus in the diabetic population, as well as the associated morbidity, mortality, and costs of ulcerations, it is imperative to correct the cause of the deforming force to cure and prevent further ulcerations. Persistent hyperglycemia often makes these procedures temporary, with evidence of recurrence seen throughout the literature varying from

Table 4 Summary of Achilles tendon lengthening for forefoot ulceration caused by equinus						
	Tenotomies (N)	% Healed (N)	% Recurrence (N)	Follow- up	% Heel Ulcers (N)	% Rupture (N)
Colen et al, <sup>46</sup> 2013	145	100% (145)	2% (3)	2.7 y	1.4% (2)	0% (0)
Mueller et al, <sup>49</sup> 2003	30	100% (30)	37% (11)	2 y	13.3% (4)	0 (0)
Holstein et al, <sup>47</sup> 2004	75	90.6% (68)	14.7% (11)	1 y	14.7% (11)	9.3% (7)
Lin et al, <sup>48</sup> 1996	15	93.3% (14)	0% (0)	17 mo	0% (0)	0% (0)
Total	265	96.9% (257)	9.43% (25)	1–2.7 y	6.4% (17)	2.6% (7)

Data from Refs.<sup>46–49</sup>



Table 5 Summary of gastrocnemius recession for forefoot ulceration caused by equinus					
	Gastrocnemius Recession (N)	Healed (%)	% Recurrence (N)	Follow- up (mo)	% Complications (N)
Dayer & Assal, <sup>29</sup> 2009	24	95.8	4.1% (1)	39.6	0% (0)
Greenhagen et al, <sup>51</sup> 2010	1	100	0% (0)	24	0% (0)
Hamilton et al, <sup>30</sup> 2005	12	100	0% (0)	14.2	0% (0)
Laborde et al, <sup>52</sup> 2008; Laborde et al, <sup>53</sup> 2009	29	95 and 90.9	14% (4)	39	0% (0)
Total	66	95.4	7.6% (5)	20–39.6	0% (0)

Data from Refs.<sup>29,30,33,50–53</sup>

1 to 3 years. Continued monitoring is necessary to evaluate for additional prophylactic release before the onset of new ulceration.

**Sub-metatarsal heads (cavus)**

**Introduction** Forefoot ulceration located at the plantar aspect of the metatarsal heads is often attributed to an equinus contracture but may be attributed to a cavus foot type and contracted plantar fascia. Although Achilles tendon lengthening or gastrocnemius recession do alleviate forefoot pressure, in a cavovarus foot type with a high calcaneal inclination angle, this may also produce an overlengthening or rupture of the Achilles tendon, leading to a calcaneal gait. Most neurologic cavus deformities are thought to happen initially because of a plantarflexed first ray, also called forefoot-driven hindfoot varus.<sup>55</sup> This overpowering of the tibialis anterior tendon by the peroneus longus leads to eventual tibialis posterior contracture, producing a hindfoot varus. Further development of the intrinsic minus foot type through neurologic degeneration leads to an imbalance of the long flexors and extensors, leading to a retrograde plantar force on the metatarsal heads.<sup>56</sup> This positioning of the foot allows the soft tissues, including the plantar fascia, to eventually contract and hold the foot in a cavovarus position with increased pressure on the forefoot while weight-bearing. In addition to the biomechanical imbalance, Ursini and colleagues<sup>57</sup> showed that type 2 diabetes mellitus leads to thickening and irregularity of the plantar fascia, worsening the contracture. The authors routinely perform the plantar fasciotomy in conjunction with a peroneus longus to brevis tenodesis in patients with forefoot or plantar first metatarsal ulceration with a cavovarus foot type, but it may have value in selective release of individual ulceration sub-lesser metatarsal heads in the cavus foot.

**Technique** Attention is directed to the medial aspect of the heel, distal to the weight-bearing surface. The toes are dorsiflexed and the plantar fascia medial band is palpated and marked. An incision, approximately 4 cm in length, is made perpendicular to the plantar fascia extending to the glabrous junction of the foot. Blunt dissection is continued down to visualize the medial plantar fascia band. Further dissection is performed to isolate the plantar fascia on its dorsal and plantar aspects, and the fascia is released from medial to lateral with a scalpel.

**Discussion** Kim and colleagues<sup>58</sup> evaluated the use of selective plantar fasciotomy for forefoot ulcerations in 36 patients and found that 56% of ulcerations healed within 6 weeks. Kitaoka and colleagues<sup>59</sup> evaluated the effect of sectioning the plantar fascia in cadavers and found that after fasciotomy the arch flattened with additional motion in



the midfoot and hindfoot joints. To date, little is written about the use of selective plantar fasciotomy and the role it may play in healing of forefoot ulceration. Further research is needed to elicit the effectiveness of this procedure and the potential morbidity associated with it.

***Sub-fifth metatarsophalangeal joint (forefoot varus)/styloid process/sub-fifth metatarsal base (forefoot varus)***

**Introduction** Plantar ulcerations occurring on the lateral column may result from relative imbalance or contracture of the tibialis anterior tendon. The tibialis anterior muscle not only functions as a dorsiflexor of the foot but also applies a varus rotation to the foot through its insertions at the medial aspect of the base of the first metatarsal and the medial cuneiform. Lateralization of this tendon through transfer to the lateral cuneiform or cuboid may reduce the deforming force and therefore decrease the lateralized pressures.

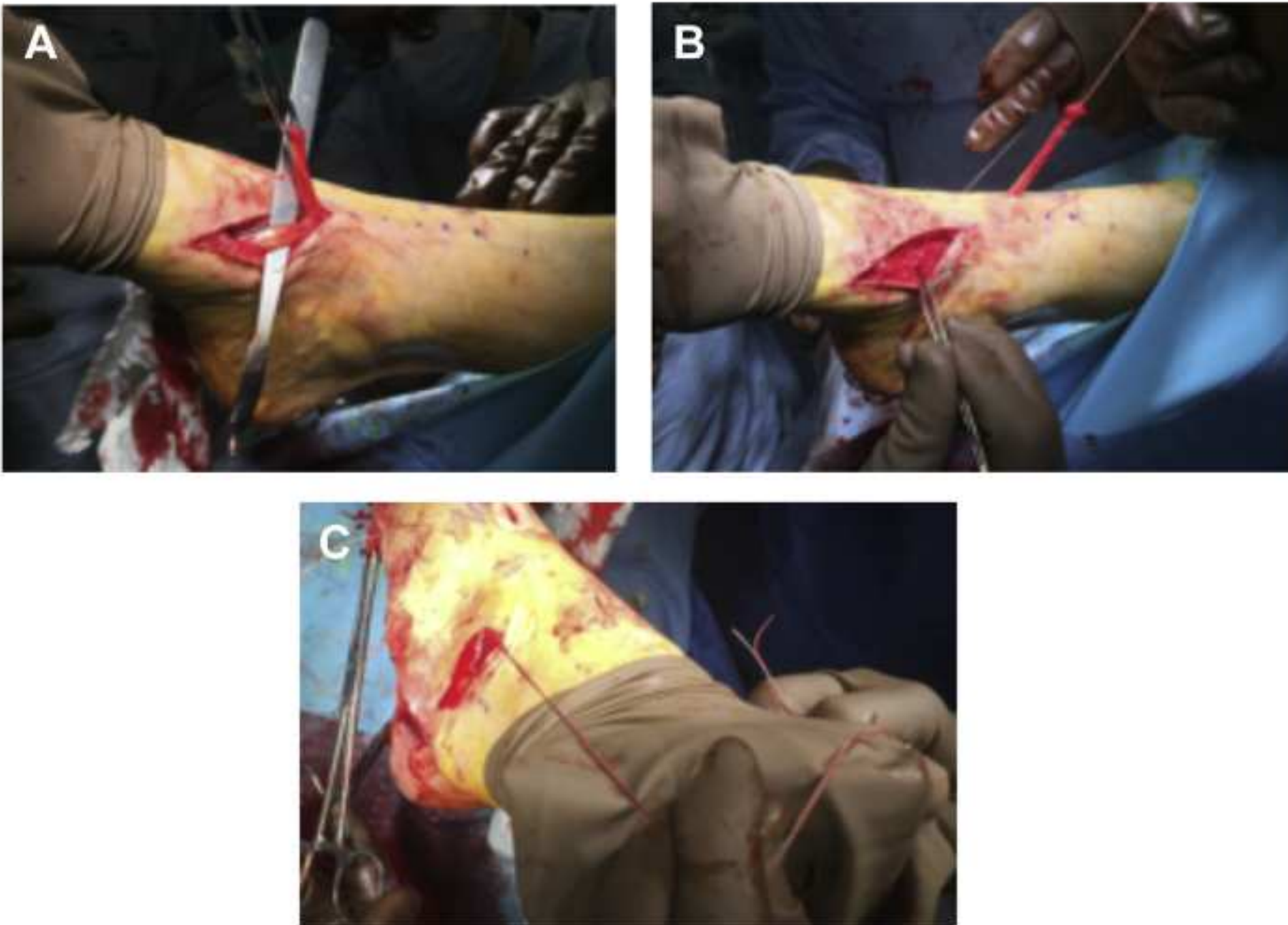
**Technique** A 3-cm incision is made medially at the insertion of the tendon, exposing the tibialis anterior tendon and its sheath. A longitudinal incision is then made through the sheath, allowing visualization of the insertion. The tendon is detached, secured with a whip stitch, and readied for transfer. A tendon passer is used to follow the tendon sheath proximally toward the ankle joint and an incision is made overlying the tendon, exposing it proximally, near the musculotendinous junction. Care is taken to protect the neurovascular bundle that lies lateral to the tendon. The tendon is passed from distal, through the proximal incision. Fluoroscopy is used to visualize the lateral cuneiform and a small incision is made dorsal to the cuneiform. A tendon passer is again used to pass the tendon from the proximal incision through subcutaneous tissues to the lateral aspect of the foot. The foot is held in dorsiflexion and eversion while the tendon is fixated to the cuneiform using an interference screw. This procedure is shown in [Fig. 5](#).

**Discussion** The tibialis anterior tendon transfer, originally described by Garceau<sup>60</sup> and popularized by Ponseti and Campos,<sup>61</sup> is traditionally performed for the management of clubfoot deformity.<sup>60,61</sup> Hoffer and colleagues<sup>62</sup> then described the split tibialis anterior tendon transfer (STATT) as a treatment option for residual clubfoot and spastic equinovarus deformity in adults. Regardless of split or full tendon transfer, the procedures neutralize the varus pull of the tibialis anterior muscle. Henderson and colleagues<sup>63</sup> compared whole tendon transfers and STATTs with regard to plantar pressures after transfer in a cadaveric model. They found that whole and split tendon transfers decreased lateral column pressures overall, with minimal difference in pressure readings between the two.<sup>63</sup> The transfer of the tibialis anterior tendon has sparse literature written about its use in offloading the lateral column in the setting of neuropathic ulcerations, but biomechanically removes a deforming force and balances the foot. Kim and colleagues<sup>64</sup> described a lengthening of the tibialis anterior tendon for lateral column ulcerations; however, long-term results are not yet known.

***Plantar central calcaneus (calcaneal gait)***

**Introduction** Ulceration of the plantar heel is most often iatrogenic through overlengthening of the Achilles tendon and creation of a calcaneal gait. As previously described, Achilles tendon lengthening and gastrocnemius recession can be used to treat recalcitrant and nonhealing forefoot ulcerations in the setting of equinus. However, overlengthening of the posterior heel cord can lead to the creation of a calcaneal gait and increased hindfoot pressures during ambulation. The Achilles tendon is overlengthened in 2% to 10% of Achilles lengthening procedures, creating this





**Fig. 5.** (A) Detachment of lateral portion of tibialis anterior tendon from insertion for transfer into the cuboid. (B) Lateral portion of STATT (split tibialis anterior tendon transfer) with suture attached. Medial portion shown with forceps remaining attached to the anatomic insertion. (C) Lateral portion of STATT rerouted into the lateral incision and readied for insertion into the cuboid with interference screw. (Courtesy of S. Masadeh, DPM, Cincinnati, OH.)

deformity.<sup>47,49,65–67</sup> These ulcerations are often initially treated conservatively through various offloading measures such as bracing, non-weight-bearing, and total contact casting, but remain difficult to manage conservatively. Previously described conservative treatments, such as total contact casting, can have a high rate of complications and a high rate of recurrence because the biomechanical cause of the problem remains uncorrected. Surgical measures are available, and include peroneus brevis transfer, flexor hallucis longus (FHL) transfer with or without calcaneal osteotomy, partial calcanectomy, below-knee amputation, ankle arthrodesis, and tibiototalcalcaneal arthrodesis. Focusing on soft tissue balancing to reduce deformity, this article evaluates the FHL transfer in isolation.

**Technique** The Achilles tendon paratenon is exposed, which is typically immediately beneath the thin subcutaneous layer. The paratenon is then opened and any pathologic tendon is debrided. Dissection is continued to expose the body of the calcaneus anterior to the insertion of the Achilles tendon, where the FHL tendon is anchored. As dissection continues, the FHL tendon can be visualized, after incising the deep fascia, coursing from lateral to medial within the surgical site. Care must be taken because the neurovascular bundle as well as the FDL course medial to the FHL. The foot is plantarflexed and the FHL tendon is transected as far distal as possible in order to harvest as much length as possible for transfer. The tendon can then be anchored into the calcaneus using a soft tissue anchor or an interference screw.<sup>68,69</sup> The anchor should be inserted at an angle of 45° in order to maximize pullout strength. The surgical site



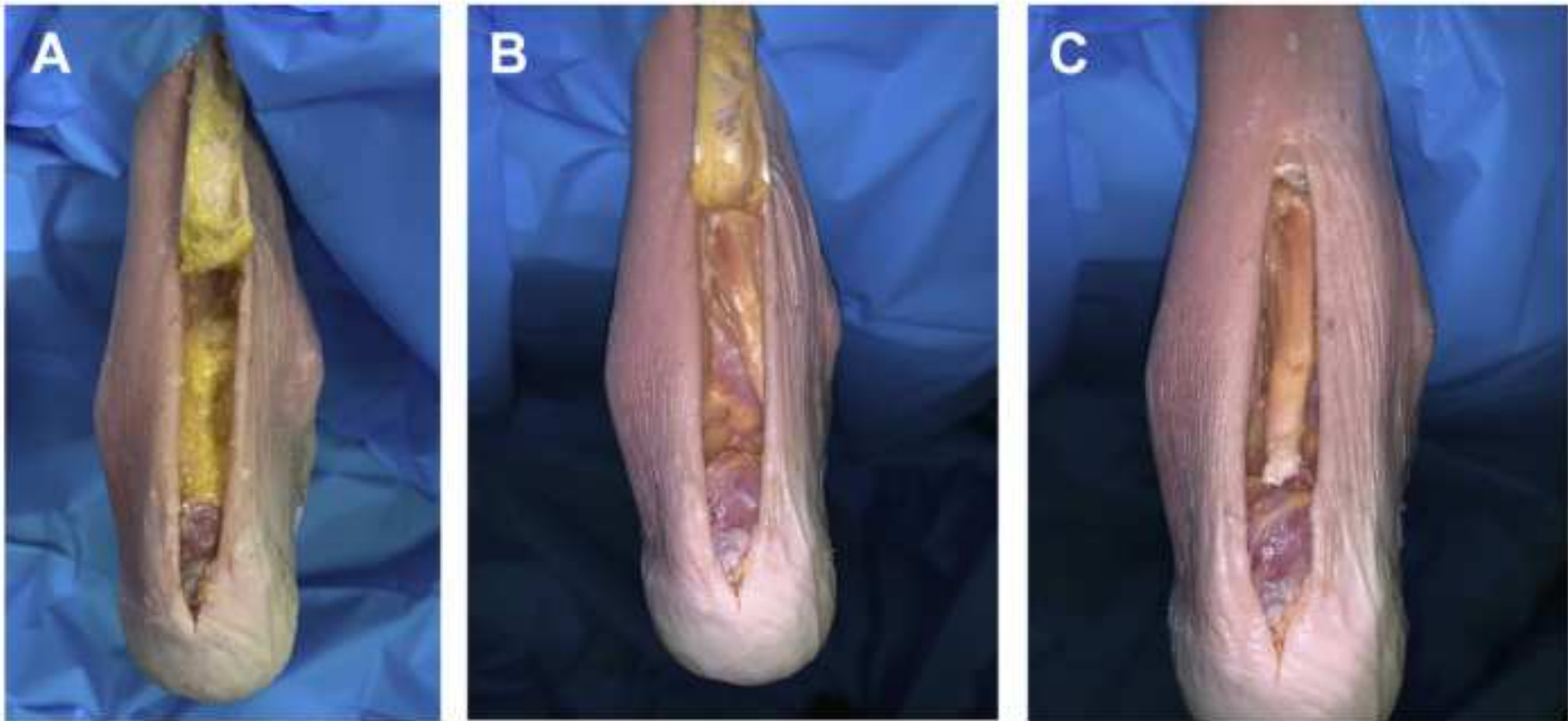
can be closed in a layered anatomic fashion and the foot should be dressed with a dry sterile dressing and splinted in about 10° of plantarflexion, as shown in Fig. 6.

**Results** There is a paucity of literature regarding FHL tendon transfer for the treatment of plantar heel ulcerations after a calcaneal gait. Hahn and colleagues<sup>70</sup> evaluated FHL transfer for the treatment of chronic/neglected Achilles tendon ruptures, with good results noted, as well as a minimal clinical and pedobarographic change in gait pattern in relation to propulsion and the first metatarsophalangeal joint complex. Kim and colleagues<sup>71</sup> retrospectively evaluated 9 patients with diabetes with chronic plantar heel ulcerations caused by calcaneal gait after Achilles tendon overlengthening. All 9 ulcerations healed within 8 weeks after undergoing FHL tendon transfer for treatment.<sup>71</sup>

**Discussion** Plantar central ulcerations and calcaneal gait are a rare complication of Achilles tendon lengthening, which is likely why there is a lack of research on this topic. There have been several studies suggesting that the FHL is superior to the peroneus brevis for transfer because of superior overall strength of the tendon.<sup>72,73</sup> Most of the literature for tendon transfer procedures for treatment of calcaneal gait is related to acute or recalcitrant Achilles tendon ruptures. More studies are needed to investigate the long-term results regarding rearfoot tendon transfers for the management and treatment of plantar heel ulcerations.

***Plantar medial calcaneus (hindfoot valgus)/plantar lateral calcaneus (hindfoot varus)***

**Introduction** Plantar medial and plantar lateral heel ulcerations are commonly cause by a hindfoot valgus or a hindfoot varus foot deformity, respectively. It is important to determine whether the inherent deformity is flexible, semirigid, or a rigid osseous deformity, because this dictates the treatment algorithm. It is also useful to assess relaxed calcaneal stance position (RCSP) and to assess whether this deformity is present throughout the gait cycle.<sup>74</sup> The RCSP is traditionally defined as the angle formed by the bisection of the posterior aspect of the calcaneus and a line drawn perpendicular to the resting surface during relaxed standing in the angle and base of gait, with a value of 0° ± 2° (varus or valgus).<sup>75</sup> Recent literature has raised concerns regarding the basis of RCSP, implying that the original definition of the value of 0° ± 2° by Root and



**Fig. 6.** (A) Exposure of the deep fascia deep to the Achilles tendon after transection of the Achilles tendon. (B) Exposed FHL tendon readied for harvest and transfer within the deep fascia. (C) Transfer of FHL tendon using interference screw at deadman's angle to optimize pullout strength. (Courtesy of S. Masadeh, DPM, Cincinnati, OH.)



colleagues<sup>75</sup> has no substantial clinical-based evidence and is merely theoretic. Recent studies have shown that the RCSP is a reliable measure of hindfoot varus and valgus clinically, but challenge the traditional values. These studies have proposed wide-ranging values of 1° varus to 14° valgus in adults, with a mean of 6.07° valgus.<sup>76–78</sup>

Imaging should also be obtained to assess for arthritic changes/rigid deformities, including Harris Beath, calcaneal axial, and hindfoot alignment views to assess the extent of hindfoot varus. In 2010, Lee and colleagues<sup>74</sup> examined the reliability and validity of the commonly used radiographic measurements to diagnose hindfoot varus and valgus. The study determined that naviculocuboid overlap, anteroposterior talonavicular coverage angle, and anteroposterior talus-first metatarsal angle were reliable measurements in distinguishing a hindfoot valgus from varus deformity.<sup>74</sup>

### Technique plantar lateral ulcerations

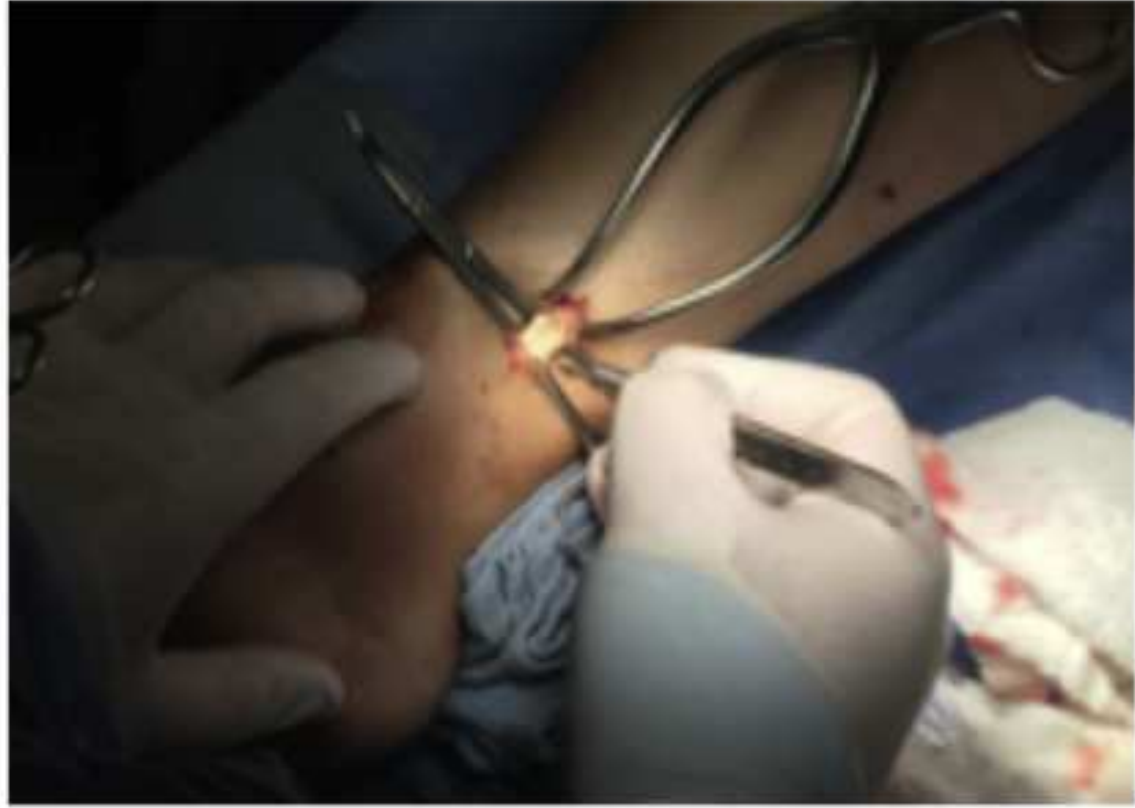**Posterior tibial tendon tenotomy/recession** At the medial ankle, just distal to the medial malleolus, a 2-cm incision is made and blunt dissection is performed to the level of the tarsal tunnel. The flexor retinaculum is incised and the posterior tibial tendon is identified. Care is taken not to damage the FDL tendon or the adjacent neurovascular bundle. The tendon is then isolated and either sharply divided or lengthened with a Z-lengthening technique and repaired with nonabsorbable suture, as shown in [Fig. 7](#). The surgical site is then closed in a layered anatomic fashion and the foot should be dressed with a dry sterile dressing.<sup>79</sup>

**Combined results** For hindfoot varus deformities, soft tissue procedures focus on lengthening, transferring, or releasing the overpowering posterior tibial tendon. As described by Huber and colleagues<sup>80</sup> and others, the cavus foot type is driven by agonist/antagonist muscles either by the peroneus longus overpowering the tibialis anterior muscle leading to a plantarflexed first ray (forefoot driven cavus) or the posterior tibial tendon overpowering the peroneus brevis (hindfoot driven varus).<sup>81,82</sup> The decision to lengthen or release versus transfer the posterior tibial tendon has traditionally been determined by whether there is a drop foot or weakness of the anterior compartment causing a steppage gait. Posterior tibial tendon transfers have traditionally been reserved for neurologic or posttraumatic causes (ie, common peroneal nerve injury to increase dorsiflexion strength).<sup>83–85</sup>

For hindfoot valgus deformities, procedures are focused on correcting the overpowering peroneus brevis muscle. The peroneus brevis, as the antagonist to the posterior tibial tendon, pulls the hindfoot into valgus if the posterior tibial tendon is weak. Peroneus brevis tendon lengthening has been described in relation to treating hindfoot valgus in patients with cerebral palsy to reduce deformity.<sup>86</sup>

**Discussion** It is important when evaluating a hindfoot varus/valgus to clinically assess the biomechanical relationship of the rearfoot to the ground. The authors propose that, in the presence of a wound on either the plantar lateral or plantar medial aspect of the calcaneus, a respective hindfoot varus or hindfoot valgus deformity is the likely cause. Clinical evaluation and judgment, including gait evaluation, and flexibility of deformity, should be used, as opposed to relying on a numerical value. Examining the motion of the hindfoot and reducibility of the deformity is imperative in its correction. A thorough lower extremity examination, including a gait examination, should be included when evaluating patients with hindfoot deformities. Failure to identify proximal deformities, especially with osseous procedures, could increase the potential for failure. Tibia/fibula, knee, hip, and limb length radiographs should be obtained for evaluation.





**Fig. 7.** Posterior tibial tendon is isolated and a Z-lengthening is performed for plantar lateral calcaneus ulcer/hindfoot varus deformity. (Courtesy of S. Masadeh, DPM, Cincinnati, OH.)

Because the procedures for hindfoot varus and valgus have only been used in relation to biomechanical deformities and neurologic or posttraumatic causes, further research is required for the use of these procedures in wound healing and ulceration prevention. Long-term studies will also be needed in order to assess for recurrences and efficacy compared with traditional conservative measures.

### SUMMARY

Diabetes currently affects approximately 9.4% of the United States population, or roughly 30.3 million citizens.<sup>87</sup> An additional 84.1 million citizens have the diagnosis of prediabetes, a disorder that often progresses to diabetes within 5 years of diagnosis.<sup>87</sup> Because of this, it can be expected that the patient population with diabetes will continue to increase over the next decade, further increasing the medical and economic demands on our society. Between \$9 billion and \$14 billion dollars was spent directly on the treatment of patients with foot ulcerations in 2015 alone, showing the severe financial implications of foot ulceration.<sup>88,89</sup> Between 15% and 25% of people with diabetes develop a foot ulceration during their lifetimes.<sup>90–92</sup> The estimated cost of treating 1 foot ulcer over a 2-year period is approximately \$28,000, with a single hospitalization event exceeding \$30,000.<sup>93,94</sup> Given the anticipated increase in the number of patients with diabetes and an annual incidence of ulceration of 2% in those with the diagnosis, it can be safely assumed that the economic burden of ulcerations will continue to increase without establishing more definitive treatment options than the current algorithms offer.<sup>2,94,95</sup>

Knowing that neuropathic ulcerations often progress to the end point of amputations if not treated appropriately in the initial clinic setting, it becomes imperative to treat preulcerative and ulcerative lesions with definitive measures early to save both economic resources and limbs. Ulcerations have been implicated as the causative factor in as many as 84% of amputations in patients with diabetes.<sup>91,96–98</sup> Up to 43% of those patients with diabetes and a foot ulcer progress to an amputation.<sup>98–100</sup> Additional amputations are often inevitable after initial amputation because of the creation of a new deformity and further altering the foot biomechanics and pressure distribution. Reamputation rates have been shown to be as



high as 26.7% after 1 year, 48.3% after 3 years, and 60.7% after 5 years, showing the importance of preventing the progression of ulceration and the initial amputation event.<sup>97,101,102</sup>

The typical initial treatment of a diabetic foot ulcer in the clinical setting is often local wound care, offloading through custom orthopedic shoes, or plaster casting to temporarily alleviate the deformity and the increased plantar pressures. These methods have shown efficacy in obtaining initial healing, but reulceration rates remain high. Reulceration rates have been seen as high as 38.8% within 1 year using custom-made footwear and 44.2% with routine care alone, as well as exceeding 60% after 3 years.<sup>4–8</sup> Studies performed by Striesow and colleagues<sup>103</sup> and Viswanathan and colleagues<sup>104</sup> have shown reulceration rates up to 67% in self-selected shoes. Armstrong and colleagues<sup>105</sup> showed an average daily adherence of approximately 28% in those patients with ulceration who were prescribed a removable foot-offloading device, and even the most strictly adherent patients were compliant with their treatment only 60% of the day. Poor outcomes associated with conservative measures are likely caused by persistent hyperglycemia leading to recurrence and poor compliance to the prescribed conservative treatment regimen. This chronic state of increased glucose levels leads to nonenzymatic glycosylation of not only tendons located in the foot and ankle but also throughout the body. Continued protein glycosylation creates contracture, deformity, and imbalance, leading to the creation of high-pressure areas within the weight-bearing surface. To adequately alleviate these increased pressures and reduce the likelihood of recurrence, the source of the deforming force needs to be corrected to regain balance.

Considering the number of current patients with active neuropathic ulceration, it can be assumed that a far greater number are currently in remission, without definitive long-term solution provided. With the greatest risk factor or predictor of ulceration being a prior history of ulceration, it is safe to assume that those patients currently healed will likely reulcerate at a future time.<sup>106</sup> It is therefore imperative to provide longer-lasting, reproducible solutions to address the root of the problem. These solutions can be achieved, in the appropriate situations, through tendon transfer and balancing, not to provide a functional transfer but to reduce the deforming forces creating the deformity itself. These procedures are performed with the intent of restoring a plantigrade, biomechanically neutral foot, improving joint mobility and reducing the associated deformity. The question remains, when should these procedures be performed? It is known that, as a patient continues along the spectrum of ulceration, it likely ends in increasing deformity and amputation. Armstrong and colleagues<sup>105</sup> established a foot surgery classification for patients with diabetes, to stratify risks as (1) elective, (2) prophylactic, (3) curative, or (4) emergent, in nonischemic diabetic patients.<sup>5,107</sup> This hierarchy of surgical classification allows practitioners to readily classify procedures within the patient population with diabetes and predict future outcomes and associated risks with the timing of intervention. This classification was further shown to provide efficacy in treating patients early on the spectrum to prevent progression to eventual amputation, limb loss, or severe postoperative complications.<sup>5,105,107</sup> As the classification level progresses, so does the likelihood of the patient experiencing a poor outcome.<sup>5,105,107</sup> This likelihood further provides support that these patients with ulceration or preulcerative lesions should be treated while in the prophylactic or preulcerative stage when possible, which can often be achieved in flexible or semirigid deformities by removing the deforming forces through the various tendon procedures, based on anatomic ulcer location, as described in this article.



## CLINICS CARE POINTS

- Persistent states of hyperglycemia lead to muscular imbalances and the creation of initial flexible deformities.
- Failure to address these deformities leads to biomechanical imbalances and the creation of areas of high pressure on the plantar foot with eventual pursuant ulceration.
- To address these deformities through tendon transfers the deformities must be flexible or semi-rigid.
- Prophylactic surgery may prevent the need for future amputations.

## DISCLOSURE

The authors have nothing to disclose.

## REFERENCES

1. Apelqvist K, Ragnarson-tennvall G, Larsson J, et al. Long term cost for foot ulcers in diabetic patients in a multidisciplinary setting. *Foot Ankle Int* 1995; 16(7):388–94.
2. Boulton AJ, Vileikyte L, Ragnarson-Tennvall G, et al. The global burden of diabetic foot disease. *Lancet* 2005;366:719–24.
3. Prompers L, Huijberts M, Schaper N, et al. Resource utilization and costs associated with the treatment of diabetic foot ulcers 2008;51(10):1826–34.
4. Apelqvist J, Larsson J, Agard CD. Long-term prognosis for diabetic patients with foot ulcers. *J Intern Med* 1993;233:485–91.
5. Armstrong DG, Boulton AJM, Bus SA. Diabetic foot ulcers and their recurrence. *N Engl J Med* 2017;376(24):2367–75.
6. Bus SA, Waaijman R, Arts M, et al. Effects of custom-made footwear on foot ulcer recurrence in diabetes: a multicenter randomized controlled trial. *Diabetes Care* 2013;36:4109–16.
7. Laborde JM. Tendon lengthening for neuropathic foot problems. *Orthopedics* 2010;33(5):319–26.
8. Pound N, Chipchase S, Treece K, et al. Ulcer-free survival following management of foot ulcers in diabetes. *Diabet Med* 2005;22(10):1306–9.
9. Kearney TP, Hunt NA, Lavery LA. Safety and effectiveness of flexor tenotomies to heal toe ulcers in persons with diabetes. *Diabetes Res Clin Pract* 2010;89: 224–6.
10. Laborde JM. Neuropathic toe ulcers treated with toe flexor tenotomies. *Foot Ankle Int* 2007;28(11):1160–4.
11. Rasmussen A, Bjerre-Christensen U, Almdal TP, et al. Percutaneous flexor tenotomy for preventing and treating toe ulcers in people with diabetes mellitus. *J Tissue Viability* 2013;22:68–73.
12. Schepers T, Berendsen HA, Oei IH, et al. Functional outcome and patient satisfaction after flexor tenotomy for plantar ulcers of the toes. *J Foot Ankle Surg* 2010;49(2):119–22.
13. Tamir E, McLaren AM, Gadgil A, et al. Outpatient percutaneous flexor tenotomies for management of diabetic claw toe deformities with ulcers: a preliminary report. *Can J Surg* 2008;51:41–4.
14. Tamir F, Vigler M, Avisar F, et al. Percutaneous tenotomy for the treatment of diabetic toe ulcers. *Foot Ankle Int* 2014;35:38–43.



15. Van Netten JJ, Bril A, van Baal JG, et al. The effect of flexor tenotomy on healing and prevention of neuropathic diabetic foot ulcers on the distal end of the toe. *J Foot Ankle Res* 2013;6:3.
16. Bakker K, Apelqvist J, Schaper NC. International working group on diabetic foot editorial board: practical guidelines on the management and prevention of the diabetic foot. *Diabetes Metab Res Rev* 2013;28:225–31.
17. Hochlenert D, Engels G, Morbach S, et al. Diabetic foot syndrome. *Nature*. Springer International Publishing AG, Springer; 2018.
18. Cowley MS, Boyko EJ, Shofer JB, et al. Foot ulcer risk and location in relation to prospective clinical assessment of foot shape and mobility among persons with diabetes. *Diabetes Res Clin Pract* 2008;82:226–32.
19. Thomas R, Brenton K, Harris B, et al. Foot ulceration in a secondary care diabetic clinic population: a 4-year prospective study. *Diabetes Res Clin Pract* 2010;90:e37–9.
20. Johnson CH, Christensen JC. Biomechanics of the first ray part I. The effects of peroneus longus function: a three-dimensional kinematic study on a cadaver model. *J Foot Ankle Surg* 1999;38(5):313–21.
21. Berndt AL, Harty M. Transchondral fractures (osteochondritis dissecans) of the talus. *J Bone Joint Surg Am* 1959;41:988–1020.
22. Glasoe WM, Yack HJ, Saltzman CL. Anatomy and biomechanics of the first ray. *Phys Ther* 1999;79:854–9.
23. Birke JA, Franks BD, Foto JG. First ray Joint limitation, pressure, and ulceration of the first metatarsal head in diabetes mellitus. *Foot Ankle Int* 1995;16(5).
24. Gibbs RC, Boxer MC. Abnormal biomechanics of feet and their cause of hyperkeratosis. *J Am Acad Dermatol* 1982;6:1061–9.
25. Michaud TM. Foot orthoses and other forms of conservative foot care. Baltimore (MD): Williams & Wilkins; 1993. p. 69–100.
26. Mueller MK, Minor SD, Diamond JE, et al. Relationship of foot deformity to ulcer location in patients with diabetes mellitus. *Phys Ther* 1990;70:356–62.
27. Roukis TS. Peroneus longus recession. *J Foot Ankle Surg* 2009;48(3):405–7.
28. DiDomenico LA, AbdelFattah SR, Hassan MK. Emerging concepts with tendon transfers. *Podiatry Today* 2018. Available at: [www.podiatrytoday.com](http://www.podiatrytoday.com).
29. Dayer R, Assal M. Chronic diabetic ulcers under the first metatarsal head treated by staged tendon balancing: a prospective cohort study. *J Bone Joint Surg Br* 2009;91(4):487–93.
30. Hamilton GA, Ford LA, Perez H, et al. Salvage of the neuropathic foot by using bone resection and tendon balancing: a retrospective review of 10 patients. *J Foot Ankle Surg* 2005;44(1):37–43.
31. Birke JA, Sims DS. Plantar sensory thresholds in the insensitive foot. *Lepr Rev* 1988;10:172–6.
32. Ctercteko GC, Dhanedran M, Hutton WC, et al. Vertical forces acting on the feet of diabetic patients with neuropathic ulceration. *Br J Surg* 1981;68:608–14.
33. Cychosz CC, Phisitkul P, Belatti DA, et al. Preventive and therapeutic strategies for diabetic foot ulcers. *Foot Ankle Int* 2016;37(3):334–43.
34. Grant WP, Sullivan R, Sonenshine DE, et al. Electron microscopic investigation of the effects of diabetes mellitus on the achilles tendon. *J Foot Ankle Surg* 1997;36:272–8.
35. Orendurff MS, Rohr ES, Sangeorzan BJ, et al. An equinus deformity of the ankle accounts for only a small amount of the increased forefoot plantar pressure in patients with diabetes. *J Bone Joint Surg Br* 2006;88:65–8.



36. Couppe C, Svensson RB, Kongsgaard M, et al. Human achilles tendon glycation and function in diabetes. *J Appl Physiol* 2016;120:130–7.
37. Boulton AJ, Hardisty CA, Betts RP, et al. Dynamic foot pressure and other studies as diagnostic and management aids in diabetic neuropathy. *Diabetes Care* 1983;6(1):26–33.
38. Frykberg RG, Lavery LA, Pham H, et al. Role of neuropathy and high foot pressures in diabetic foot ulcerations. *Diabetes Care* 1998;21:1714.
39. Lavery LA, Armstrong DG, Wunderlich RP, et al. Predictive value of foot pressure assessment as part of a population-based diabetes disease management program. *Diabetes Care* 2003;26(4):1069–73.
40. Veves A, Murray HJ, Young MJ, et al. The risk foot ulceration in diabetic patients with high foot pressure: a prospective study. *Diabetologia* 1992;35(7):660–3.
41. Frykberg RG, Bown J, Hall J, et al. Prevalence of equinus in diabetic versus nondiabetic patients. *J Am Podiatr Med Assoc* 2012;102(2):84–8.
42. Lavery LA, Armstrong DG, Boulton AJ. Diabetes Research Group: ankle equinus deformity and its relationship to high plantar in a large population with diabetes mellitus. *J Am Podiatr Med Assoc* 2002;92:479.
43. Alazzawi S, Sukeik M, King D, et al. Foot and ankle history and clinical examination: a guide to everyday practice. *World J Orthop* 2017;18(1):21–9.
44. Barske HL, DiGiovanni BF, Douglass M, et al. Current Concepts Review: isolated gastrocnemius contracture and gastrocnemius recession. *Foot Ankle Int* 2012;33(10):915–21.
45. Patel A, DiGiovanni BF. Association between plantar fasciitis and isolated contracture of the gastrocnemius. *Foot Ankle Int* 2011;32(1):5–8.
46. Colen LB, Kim CJ, Grant WP, et al. Achilles tendon lengthening: friend or foe in the diabetic foot? *Plast Reconstr Surg* 2013;131:37e–43e.
47. Holstein P, Lohman M, Bitsch M, et al. Achilles tendon lengthening, the panacea for plantar forefoot ulcers? *Diabetes Metab Res Rev* 2004;20:S37–40.
48. Lin SS, Lee TH, Wapner KL. Plantar forefoot ulceration with equinus deformity of the ankle in diabetic patients; the effect of tendo-achilles lengthening and total contact casting. *Orthopedics* 1996;19(5):465–75.
49. Mueller MJ, Sinacore DR, Hastings MK, et al. Effect of Achilles tendon lengthening on neuropathic plantar ulcers, a randomized clinical trial. *J Bone Joint Surg Am* 2003;85-A:1436–45.
50. Cychosz CC, Phisitkul P, Belatti DA, et al. Gastrocnemius recession for foot and ankle conditions in adults: evidence-based recommendations. *Foot Ankle Surg* 2015;21:77–85.
51. Greenhagen RM, Johnson AR, Peterson MC, et al. Gastrocnemius recession as an alternative to tendoachilles lengthening for relief of forefoot pressure in a patient with peripheral neuropathy: a case report and description of a technical modification. *J Foot Ankle Surg* 2010;49(2):159.
52. Laborde JM. Neuropathic plantar forefoot ulcers treated with tendon lengthenings. *Foot Ankle Int* 2008;29(4):378–84.
53. Laborde JM. Midfoot ulcers treated with gastrocnemius soleus recession. *Foot Ankle Int* 2009;30(9):842–6.
54. Armstrong DG, Stacpoole-Shea S, Nguyen H, et al. Lengthening of the Achilles tendon in diabetic patients who are at high risk for ulceration of the foot. *J Bone Joint Surg Am* 1999;81(4):535–8.
55. Coughlin MJ, Mann RA. *Surgery of the foot and ankle*. 7th edition. St Louis (MO): Mosby Inc; 1999.



56. Lippman HI, Perotto A, Farrar R. The neuropathic foot of the diabetic. *Bull N Y Acad Med* 1976;52(10):1159–78.
57. Ursini F, Arturi F, Nicolosi K, et al. Plantar fascia enthesopathy is highly prevalent in diabetic patients without peripheral neuropathy and correlates with retinopathy and impaired kidney function. *PLoS One* 2017;12(3):e0174529.
58. Kim JY, Hwang S, Lee Y. Selective plantar fascia release for nonhealing diabetic plantar ulcerations. *J Bone Joint Surg Am* 2012;94(14):1297–302.
59. Kitaoka HB, Luo ZP, An KN. Effect of plantar fasciotomy on stability of the arch of the foot. *Clin Orthop Relat Res* 1997;344:307–12.
60. Garceau GJ. Anterior tibial tendon transposition in recurrent congenital clubfoot. *J Bone Joint Surg Am* 1940;22:932–6.
61. Ponseti IV, Campos J. The classic: observations on pathogenesis and treatment of congenital clubfoot. 1972. *Clin Orthop Relat Res* 2009;467:1124–32.
62. Hoffer MM, Reiswig JA, Garrett AM, et al. The split anterior tibial tendon transfer in the treatment of spastic varus hindfoot of childhood. *Orthop Clin North Am* 1974;5:31–8.
63. Henderson CP, Parks BG, Guyton GP. Lateral and medial pressures after split versus whole anterior tibialis tendon transfer. *Foot Ankle Int* 2008;29(10):1038–41.
64. Kim P, Steinberg J, Kikuchi M, et al. Tibialis anterior tendon lengthening: adjunctive treatment of plantar lateral column diabetic ulcers. *J Foot Ankle Surg* 2015;54(4):686–91.
65. Chilvers M, Malicky ES, Anderson JG, et al. Heel overload associated with heel cord insufficiency. *Foot Ankle Int* 2007;28(6):687–9.
66. Nishimoto GS, Attinger CE, Cooper PS. Lengthening of the Achilles tendon for the treatment of diabetic plantar forefoot ulceration. *Surg Clin* 2003;83(3):707–26.
67. Schweinberger MH, Roukis TS. Surgical correction of soft-tissue ankle equinus contracture. *Clin Podiatr Med Surg* 2008;25(4):571–85.
68. Burkhart SS, Lo IKY, Brady PC. Burkhart's view of the shoulder: a cowboy's guide to advanced shoulder arthroscopy. Philadelphia: Lippincott Williams & Wilkins; 2006.
69. Strauss E, Frank D, Kubiak E, et al. The effect of the ankle of suture anchor insertion on fixation failure at the tendon-suture interface after rotator cuff repair: deadman's angle revisited. *Arthroscopy* 2009;25:597.
70. Hahn F, Maiwald C, Horstmann T, et al. Changes in plantar pressure distribution after achilles tendon augmentation with flexor hallucis longus transfer. *Clin Biomech (Bristol, Avon)* 2008;23(1):109–16.
71. Kim J-Y, Lee I, Seo K, et al. FHL tendon transfer in diabetics for treatment of non-healing plantar heel ulcers. *Foot Ankle Int* 2010;31(6):480–5.
72. Sebastian H, Datta B, Maffulli N, et al. Mechanical properties of reconstructed Achilles tendon with transfer of peroneus brevis or flexor hallucis longus tendon. *J Foot Ankle Surg* 2007;46(6):424–8.
73. Silver RL, de la Garza K, Rang M. The myth of muscle balance: a study of relative strengths and excursions of normal muscles about the foot and ankle. *J Bone Joint Surg Br* 1985;67:432–7.
74. Lee KM, Chung CY, Park MS, et al. Reliability and validity of radiographic measurements in hindfoot varus and valgus. *J Bone Joint Surg Am* 2010;92(13):2319–27.



75. Root ML, Orien WP, Weed JH. Biomechanical examination of the foot. Los Angeles (CA): Clinical Biomechanics corp; 1971.
76. Payne C, Richardson M. Changes in measurement of neutral and relaxed calcaneal stance positions with experience. *Foot* 2000;10(2):81–3.
77. Sobel E, Levitz SJ, Caselli MA, et al. Reevaluation of the relaxed calcaneal stance position. Reliability and normal values in children and adults. *J Am Podiatr Med Assoc* 1999;89(5):258–64.
78. Weiner-Oglivie S, Rome K. The reliability of three techniques for measuring foot position. *J Am Podiatr Med Assoc* 1998;88(8):381–6.
79. Redfern JC, Thordarson DB. Achilles lengthening/posterior tibial tenotomy with immediate weightbearing for patients with significant comorbidities. *Foot Ankle Int* 2008;29(3):325–8.
80. Huber M. What is the role of tendon transfer in the cavus foot. *Foot Ankle Clin* 2013;18(4):689–95.
81. Chilvers M, Manoli A. The subtle cavus foot and association with ankle instability and lateral foot overload. *Foot Ankle Clin* 2008;13(2):315–24.
82. Rosenbaum AJ, Lisella J, Patel N, et al. The cavus foot. *Med Clin* 2014;98(2):301–12.
83. Mayer L. The physiologic method of tendon transplantation in the treatment of paralytic drop-foot. *J Bone Joint Surg Am* 1937;19(2):389–94.
84. Richardson DR, Nathan LG. The bridle procedure. *Foot Ankle Clin* 2011;16(3):419–33.
85. Rodriguez RP. The bridle procedure in the treatment of paralysis of the foot. *Foot Ankle* 1992;13(2):63–9.
86. Nather A, Bee CD, Huak CY, et al. Epidemiology of diabetic foot problems and predictive factors for limb. *J Diabetes Complications* 2008;22:77–82.
87. Centers for Disease Control and Prevention. National diabetes statistics report. Atlanta (GA): Centers for Disease Control and Prevention, U.S. Department of Health and Human Services; 2017.
88. Rice JB, Desai U, Cummings AK, et al. Burden of diabetic foot ulcers for medicare and private insurers. *Diabetes Care* 2014;37(3):651–8.
89. Singer AJ, Tassiopoulos A, Kirsner RS. Evaluation and management of lower extremity ulcers. *N Engl J Med* 2017;377:1559–67.
90. Bakker K, Haper NS. The development of global consensus guidelines on the management and prevention of the diabetic foot 2011. *Diabetes Metab Res Rev* 2012;28:116–8.
91. Pecoraro RE, Reiber GE, Burgess EM. Pathways to diabetic limb amputation. Basis for prevention. *Diabetes Care* 1990;13:513–21.
92. Singh N, Armstrong DG, Lipsky BA. Preventing foot ulcers in patients with diabetes. *J Am Med Assoc* 2005;293:217–28.
93. Hicks CW, Selvarajah S, Mathiodoudakis N, et al. Trends and determinants of costs associated with the inpatient care of diabetic foot ulcers. *J Vasc Surg* 2014;60(5):1247–54.
94. Ramsey SD, Newton K, Blough D, et al. Incidence outcomes and costs of foot ulcers in patients with diabetes. *Diabetes Care* 1999;22:382–7.
95. Schaper NC, Van Netten JJ, Apelqvist J, et al. Prevention and management of foot problems in diabetes: a summary guidance for daily practice based on the 2015 IWGDF guidance documents. *Diabetes Metab Res Rev* 2016. <https://doi.org/10.1002/dmrr.2695>.
96. Frykberg RG, Zgonis T, Armstrong DG, et al. Diabetic foot disorders: a clinical practice guideline. *J Foot Ankle Surg* 2006;45:S1–66.



97. Larsson J, Agardh CD, Apelqvist J, et al. Long-term prognosis after healed amputation in patients with diabetes. *Clin Orthop Relat Res* 1998;350:149–58.
98. Moss SE, Klein BE. Long-term incidence of lower-extremity amputation in a diabetic population. *Arch Fam Med* 1996;5:391–8.
99. Connel FA, Shaw C, Will J. Lower extremity amputations among persons with diabetes mellitus. *Morb Mortal Wkly Rep* 1991;40:737–9.
100. Reiber GE, Boyko EJ, Smith DG. Lower extremity foot ulcers and amputations in diabetes. In: Harris MI, Cowie C, Stern MP, editors. *Diabetes in America*. 2nd edition. Bethesda (MD): National Institutes of Health; 1995. p. 409–28.
101. Chu YJ, Li XW, Wang PH, et al. Clinical outcomes of toe amputation in patients with type 2 diabetes in Tianjin, China. *Int Wound J* 2016;13(2):175–81.
102. Izumi Y, Satterfield K, Lee S, et al. Risk of reamputation in diabetic patients stratified by limb and level of amputation: a 10-year observation. *Diabetes Care* 2006;29(3):566–70.
103. Striesow F. Special manufactured shoes for prevention of recurrent ulcer in diabetic foot syndrome. *Med Klin* 1998;93(12):695–700.
104. Viswanathan V, Madhavan S, Gnanasundaram S, et al. Effectiveness of different types of footwear insoles for the diabetic neuropathic foot. *Diabetes Care* 2004;27:474–7.
105. Armstrong DG, Lavery LA, Kimbriel HR, et al. Activity patterns of patients with diabetic foot ulceration. *Diabetes Care* 2003;26(9):2595–997.
106. Monteiro-Soares M, Boyko EJ, Ribeiro J, et al. Predictive factors for diabetic foot ulceration: a systematic review. *Diabetes Metab Res Rev* 2012;28:574–600.
107. Armstrong DG, Frykberg RG. Classifying diabetic foot surgery: toward a rational definition. *Diabet Med* 2003;20:329–31.